



ELSEVIER

Theriogenology 58 (2002) 1425–1433

Theriogenology

Ultrasonographic measurements of accessory sex glands, ampullae, and urethra of normal stallions of various size types

M.A. Pozor^{a,b,*}, S.M. McDonnell^a

^a*Equine Behavior Laboratory, New Bolton Center, University of Pennsylvania School of Veterinary Medicine, 382 West Street Road, Kennett Square, PA 19348, USA*

^b*Department of Animal Reproduction, University of Agriculture, 30-059 Krakow, Poland*

Received 12 June 2001; received in revised form 1 March 2002; accepted 4 June 2002

Abstract

For the purpose of establishing clinical reference values, this paper reports results of ultrasonographic examination and measurement of accessory sex glands, ampullae, and the pelvic urethra of 102 mature, healthy breeding stallions (2–29 years of age) of various size types (7 Miniature Horses, 27 small ponies, 53 light horses and 15 heavy horses). Examinations were done per rectum in mostly unsedated stallions using an Aloka 210 scanner with a 7.5 MHz linear veterinary transrectal transducer (Corometrics Medical Systems, Inc., North Wallingford, CT, USA). Most measures of accessory sex glands, ampullae and the urethra were larger in horses of larger sizes. Except for vesicular glands, the majority of the measures for all glands were smaller for Miniature Horses and ponies than for light horses and heavy horses ($P < 0.05$). For vesicular glands, measures for heavy horses were greater than for those of other groups ($P < 0.05$). Measures were similar for Miniature Horses and ponies, and for light horses and heavy horses. For all measures, differences between left and right paired glands were not different ($P > 0.10$). The lumen diameter of vesicular glands and ampullae as well as prostate lobe thickness showed the greatest asymmetry. Although there were too few representatives of various breeds for statistical comparison, among the light horse breeds Arabian stallions had the smallest mean values for the majority of the measures. Among stallions, echogenic characteristics of accessory sex glands, particularly vesicular glands, varied widely, possibly related to variation in recent sexual activity. For some stallions, echogenic character, particularly that of vesicular glands, varied remarkably from left to right gland within stallions. For ampullae, there was also wide variation in lumen contents between stallions. These data are generally consistent with previous reports with smaller numbers of stallions, as well as consistent with in vitro measures in

* Corresponding author. Present address: College of Veterinary Medicine, University of Florida, Gainesville, Florida 32610-0136, USA. Tel.: +1-352-392-4700x4075; fax: +1-352-392-8289.

E-mail addresses: pozorm@mail.vetmed.ufl.edu (M.A. Pozor), suemcd@vet.upenn.edu (S.M. McDonnell).

previous studies. The results provide useful clinical guidelines for size measures of accessory sex glands in horses.

© 2002 Elsevier Science Inc. All rights reserved.

Keywords: Stallion; Accessory sex glands; Pelvic ultrasonographic

1. Introduction

The technique of ultrasonographic imaging of accessory sex glands as a useful adjunct to clinical evaluation of stallions was first introduced by Little and Woods in 1987 [1]. In that and subsequent reports these and other authors described ultrasonographic characteristics, size measures, and dynamic changes in size and character in small numbers of horse and pony [1–5]. Subsequently, considerable information has been published on the technique, providing sample images of normal glands and of pathologic changes [6–8]. This method has proven to be the only tool for a clinician to objectively evaluate the majority of the structures of internal genitalia of the stallion. However, it has not become a popular practice due to the belief that it could be dangerous to both the veterinarian and the stallion.

To date, measures of ultrasonographic imaged accessory sex glands of stallions have not been published for a larger sample of stallions. This paper reports the size and character of ultrasonographic imaged accessory sex glands of 102 stallions representing each of the four major size types (Miniature Horse, pony, light horse, and heavy horse).

2. Materials and methods

A total of 102 stallions were examined. These included seven Miniature Horses (3–12 years of age, weighing 73–132 kg), 27 ponies (2–21 years, weighing 108–235 kg), 53 light horses (3–29 years, weighing 330–575 kg), and 15 heavy horses (2–24 years, weighing 541–833 kg). The light horse group included 9 Arabians, 9 Thoroughbreds, 20 Standardbreds, 15 other light horse breeds (Appaloosa, Paint, Warmblood and crossbred). Heavy horses included 12 Percherons and 3 Belgians. These stallions were all in active breeding programs and were examined either on their resident farm or at our reproduction referral clinic. No fertility problems were known or suspected in any of the stallions. Thirty-four stallions were examined immediately after semen collection. Sixty-eight were examined while at sexual rest.

An Aloka 210 ultrasonographic scanner with a 7.5 MHz linear veterinary transrectal transducer was used (Corometrics Medical Systems, Inc., North Wallingford, CT, USA). Stallions were restrained by halter in stocks or with the hind quarters positioned at the doorway of a box stall. Fourteen subjects were sedated with xylazine. Of these only four were judged to require sedation for safe compliance with the examination. For the remaining 10 stallions, the farm management requested that their stallions be sedated for the procedure.

In order to obtain relaxation of the stallion for examination per rectum, the anus was gently massaged until the anal sphincter relaxed and the stallion stood quietly (usually 1–2 min). Using copious lubricant the hand was then slowly introduced rectally and feces were evacuated. Accessory glands, urethra, and ampullae of deferent ducts were each

located manually, before introducing the transducer. Following previously described methods for locating and visualizing each structure [2,6], 20 specific measures were recorded. These included length and height of each bulbourethral gland; maximum dorsal-ventral thickness of each lobe and of the isthmus of the prostate; total diameter, wall thickness, and lumen diameter of each vesicular gland and each ampulla of deferent duct at their most distended portion; and total diameter of the urethra caudal to the seminal colliculus. Whenever the ultrasonographic image of a structure differed from previously described as normal, a complete breeding soundness evaluation was performed with particular attention to semen evaluation [9].

2.1. Statistical analysis

Mean differences among size types were tested using simple one-way ANOVA followed by LSD comparisons of means (Analytical Software—Statistix, Tallahassee, FL). Paired *t*-test procedures were used to compare measures of left and right structures.

3. Results

Means and ranges for each measure by size-type are shown in Table 1. Except for vesicular glands, the majority of the measures for all glands were smaller for miniature horses and ponies than for light horses and heavy horses ($P < 0.05$). For vesicular glands,

Table 1
Dimensions of accessory sex glands, ampullae and urethra in 102 stallions of various size types¹

| | Miniature Horse (<i>n</i> = 7) | Pony (<i>n</i> = 27) | Light horse (<i>n</i> = 53) | Heavy horse (<i>n</i> = 15) |
|----------------------------|------------------------------------|--------------------------|---------------------------------|---------------------------------|
| Bulbourethral gland | | | | |
| Length | 21 ^a (16–27) | 28 ^b (21–39) | 38 ^c (17–59) | 35 ^c (30–44) |
| Height | 14 ^a (11–19) | 17 ^a (10–24) | 24 ^b (12–39) | 22 ^b (16–33) |
| Prostate | | | | |
| Lobe thickness | 18 ^a (11–29) | 20 ^a (14–27) | 25 ^b (10–40) | 27 ^b (18–39) |
| Isthmus thickness | 8 ^a (4–11) | 7 ^{a,b} (2–16) | 10 ^b (4–25) | 11 ^b (5–31) |
| Vesicular gland | | | | |
| Total diameter | 9 ^a (5–15) | 12 ^a (3–30) | 12 ^a (4–20) | 16 ^b (8–43) |
| Wall diameter | 3 ^a (1–6) | 4 ^a (1–10) | 4 ^a (1–8) | 3 ^a (1–4) |
| Lumen diameter | 4 ^a (2–11) | 6 ^a (1–26) | 5 ^a (0–11) | 11 ^b (2–39) |
| Ampulla | | | | |
| Total diameter | 10 ^{a,b} (5–20) | 8 ^a (4–12) | 11 ^{b,c} (4–18) | 13 ^c (6–17) |
| Wall diameter | 4 ^a (2–10) | 3 ^a (1–5) | 5 ^b (2–8) | 5 ^b (3–7) |
| Lumen diameter | 1 ^a (0–3) | 1 ^a (0–2) | 2 ^a (0–6) | 2 ^a (0–4) |
| Urethra | | | | |
| Total diameter | 15 ^a (10–20) | 19 ^b (13–24) | 26 ^c (14–35) | 30 ^d (24–38) |

Values with different superscripts across different rows (a–d) differ significantly ($P < 0.05$).

¹Mean (range) is expressed in mm.

Table 2
Asymmetry of paired accessory sex glands and ampullae of 102 stallions

| | Percentage difference (smaller = 100%) | |
|---------------------|--|---------|
| | Mean | Range |
| Bulbourethral gland | | |
| Length | 12.2 | 0–79.5 |
| Height | 14.3 | 0–57.1 |
| Prostate | | |
| Lobe thickness | 14.1 | 0–383.3 |
| Vesicular gland | | |
| Total diameter | 34.7 | 0–183.3 |
| Wall diameter | 39.7 | 0–300 |
| Lumen diameter | 81.4 | 0–700 |
| Ampulla | | |
| Total diameter | 9.1 | 0–33.3 |
| Wall diameter | 22.1 | 0–133.3 |
| Lumen diameter | 81.3 | 0–300 |

measures for heavy horses were greater than for those of other groups ($P < 0.05$). Measures were similar for Miniature Horses and ponies and for light horses and heavy horses.

For all measures, mean differences between left and right paired glands were not different ($P > 0.10$). Table 2 summarizes percentage differences between paired glands within stallions. Lumen diameter of vesicular glands and ampullae as well as prostate lobe thickness showed the greatest asymmetry.

Results by breed are summarized in Table 3. The Trakehners, Holsteiners, Appaloosas, and Paints were of similar body height and weight and so were grouped. There were too few subjects to warrant statistical analysis of breed differences; however it is of note that among the light horse breeds in this sample, Arabian stallions had the smallest mean values for the majority of the measures.

Among stallions, echogenic characteristics of accessory sex glands varied widely, apparently dependent upon recent sexual activity. This was particularly the case for vesicular glands (Fig. 1). Following prolonged teasing without ejaculation, vesicular gland contents were more highly echogenic indicating greater density. For some stallions, echogenic character, particularly that of vesicular glands, varied remarkably from left to right gland. However, we did not identify inflammatory cells on stained preparations of semen of these stallions. For ampullae, there was also wide variation between stallions in echogenicity of lumen contents (Fig. 2). We did not observe problems with ejaculation or other indications of obstruction of ampullae of deferent ducts in any of these stallions.

4. Discussion

These data provide guidelines for size measures of accessory sex glands in stallions. Most measures of accessory sex glands, ampullae and the urethra were larger in horses of

Table 3
Dimensions of accessory sex glands, ampullae and urethra in 53 light horses of various breeds

| | Arabian (n = 9) | Thoroughbred (n = 9) | Standardbred (n = 20) | Trakehner, Holsteiner, Appaloosa, Paint (n = 5) | Other Warmblood, Warmblood cross (n = 10) |
|----------------------------|--------------------|-------------------------|--------------------------|---|---|
| Bulbourethral gland | | | | | |
| Length | 31 (17–42) | 37 (28–59) | 41 (30–54) | 37 (33–40) | 40 (33–57) |
| Height | 20 (12–29) | 23 (15–39) | 27 (14–32) | 24 (17–30) | 23 (18–30) |
| Prostate | | | | | |
| Lobe thickness | 21 (16–28) | 27 (15–40) | 26 (10–35) | 27 (18–35) | 27 (19–33) |
| Isthmus thickness | 7 (4–11) | 8 (4–17) | 12 (6–22) | 12 (4–25) | 10 (4–16) |
| Vesicular gland | | | | | |
| Total diameter | 8 (4–14) | 14 (4–19) | 13 (5–20) | 10 (4–14) | 12 (4–18) |
| Wall diameter | 3 (1–5) | 3 (1–7) | 4 (1–8) | 3 (2–4) | 4 (1–8) |
| Lumen diameter | 3 (0–7) | 7 (1–10) | 5 (1–11) | 4 (1–7) | 4 (1–7) |
| Ampulla | | | | | |
| Total diameter | 10 (4–13) | 11 (7–15) | 13 (16–18) | 10 (6–18) | 11 (8–13) |
| Wall diameter | 5 (2–8) | 5 (2–7) | 5 (2–7) | 4 (2–7) | 4 (3–5) |
| Lumen diameter | 1 (0–2) | 2 (0–6) | 2 (0–5) | 2 (0–5) | 2 (1–4) |
| Urethra | | | | | |
| Total diameter | 25 (15–35) | 23 (14–31) | 28 (19–33) | 29 (25–35) | 25 (18–33) |

larger sizes. However, given the wide variation in the size of horses in this sample, corresponding differences in measures of accessory sex glands were not as great as might be expected. The relationship between size type of stallions and measures of accessory sex glands and ampullae was found to be similar in an early *in vitro* study of stallion reproductive tracts obtained at slaughter (Kosiniak K. Stallion semen plasma—production and properties of components. Unpublished postdoctoral dissertation (in Polish), Agricultural University of Krakow, Poland, 1987).

Our results are also comparable to previously reported mean measures of accessory sex glands for small groups of horse and pony stallions [1,2]. Recently, Little [6] published mean ultrasonographic measures of maximum dorsoventral gland diameters of ampullae, prostate and bulbourethral glands, based on evaluations of 20 mature, nonstimulated stallions. The measures of the ampullae and the prostates of these stallions are larger than those obtained in the present study for light horses and heavy horses. The breeds and sizes of these stallions were not reported. Also, in another report of ultrasonographic evaluation of the accessory sex glands of heavy type stallions, measures are slightly greater than we found for heavy horses [10]. The authors of this short report indicated that they were able to identify vesicular glands only in a case of chronic vesiculitis and in another case of a stallion that was sexually stimulated. This may suggest differences among studies in technique of ultrasonographic evaluation. We have observed that slight differences in pressure applied to the ultrasonographic transducer may result in variations in values of measures of these very small structures. Also, for that work a 5 MHz transducer was used, while a 7.5 MHz transducer was used in the work reported here. No doubt considerable improvements in equipment and technique will lead to further increases in imaging ability and quality.

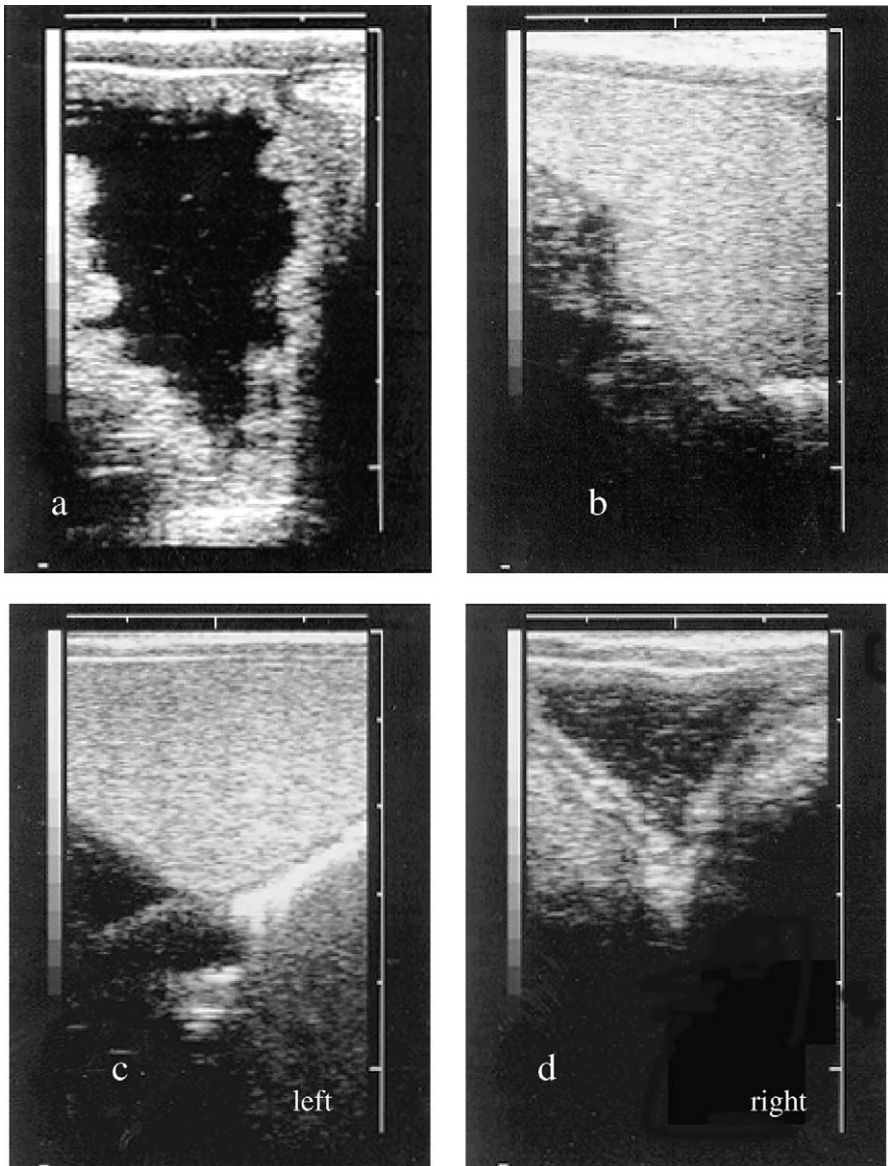


Fig. 1. Examples of ultrasound images of vesicular glands: (a) most typical—large, echolucent lumen; (b) large, echogenic lumen; (c) and (d) images of left and right vesicular glands of one stallion.

For many of the stallions evaluated in this study, the size and character of lumen contents varied remarkably between paired glands. This finding is important in clinical evaluation. Malmgren [11] suggested that highly echogenic character of the lumen of vesicular glands, particularly with a difference between paired glands, indicated possible inflammation. In

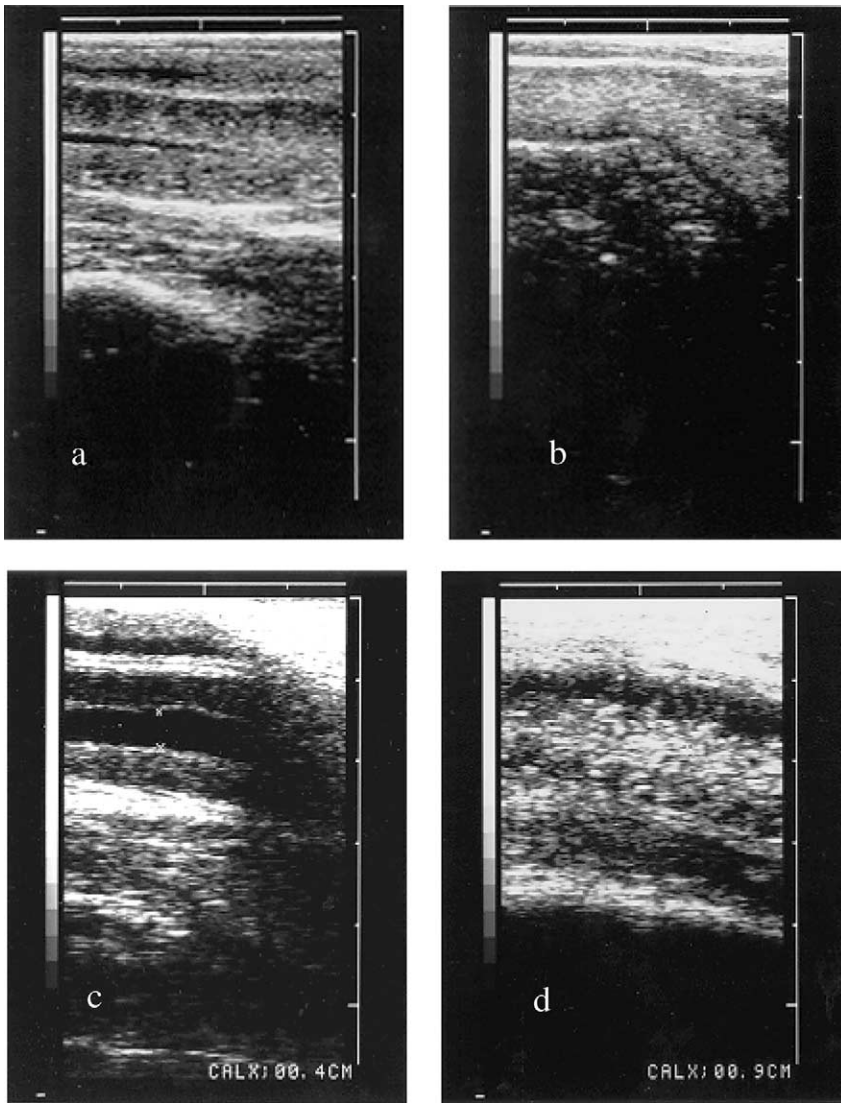


Fig. 2. Examples of ultrasound images of ampullae of deferent ducts—longitudinal sections: (a) most typical—with small, echolucent lumen; (b) uniform echogenicity—lumen not visible; (c) wide, echolucent lumen; (d) wide, echogenic lumen.

the current study, we saw great variation in echogenic character within and between stallions that were all known to have semen free of inflammatory cells. Therefore, we can conclude that highly echogenic gland contents does not necessarily indicate inflammation.

There are no studies evaluating the variation in size within stallion due to season. As there are seasonal differences in volume and sperm concentration in stallions, it can be expected that there would be corresponding differences in gland measures.

In this study and in general stallion clinical practice there are several other factors about which little is known that may affect size and character of accessory sex glands. One factor that may obviously affect accessory sex gland size and contents is interval from ejaculation at the time of examination. Weber et al. [2] showed that dimensions of accessory sex glands in stallions, except wall diameter of ampullae and vesicular glands, increase after sexual preparation and decrease immediately after ejaculation. However, in majority of cases there were no significant differences between measures taken before sexual preparation and immediately after ejaculation. Only total diameter of ampullae and vesicular glands, as well as luminal diameter of vesicular glands were significantly lower after ejaculation than before sexual preparation. In this sample of 102 stallions, 34 were examined within 1 h after ejaculation while the remaining 68 had variable ejaculation intervals ranging from days to months. Replication of the analyses of a subset of this sample excluding the 34 stallions examined within an hour of ejaculation yielded the same results concerning variation among size types of stallions. Similarly, work specifically addressing age, reproductive history, and sedation for examination and other factors would add to our understanding to observed variation. It has been found that accessory sex gland size and content varied with the sociosexual environment, where stallion with harem status had larger glands than those with bachelor stallion status [12].

Acknowledgements

This is a Dorothy Russell Havemeyer Foundation project. Drs. Regina Turner, Charles Love, and Nancy Diehl provided advice and/or assistance with access to stallions.

References

- [1] Little TV, Woods GL. Ultrasonography of accessory sex glands in the stallion. *J Reprod Fertil* 1987;35(Suppl):87–94.
- [2] Weber JA, Geary RT, Woods GL. Changes in accessory sex glands of stallions after sexual preparation and ejaculation. *J Am Vet Med Assoc* 1990;196:1084–9.
- [3] Weber JA, Woods GL. A technique for transrectal ultrasonography of stallions during ejaculation. *Theriogenology* 1991;36:831–7.
- [4] Weber JA, Woods GL. Transrectal ultrasonography for the evaluation of stallion accessory sex glands. *Vet Clin North Am Equine Pract* 1992;8:183–90.
- [5] Weber JA, Woods GL. Ultrasonographic measurement of stallion accessory sex glands and excurrent ducts during emission and ejaculation. *Biol Reprod* 1993;49:267–73.
- [6] Little TV. Accessory sex gland and internal reproductive tract evaluation. In: Rantanen NW, McKinnon AO, editors. *Equine diagnostic ultrasonography*. Philadelphia: Williams and Wilkins, 1998. p. 271–87.
- [7] Turner RM. Ultrasonography of the genital tract of the stallion. In: Reef VB, editor. *Equine diagnostic ultrasonographic*. Philadelphia: Saunders, 1998. p. 446–79.
- [8] Weber JA. Stallion. In: Ginther OJ, editor. *Ultrasonic imaging and animal reproduction: horses*. Cross Plains, WI: Equiservices Publishing, 1995. p. 309–34.
- [9] Kenney RM, Hurtgen, JP, Pierson R, Witherspoon D, Simons, J. *Clinical fertility evaluation of the stallion*. Hastings, Nebraska: Society for Theriogenology, 1983.
- [10] Behn C, Von Frey W, Saelzer P. Ultrasonographic evaluation of the accessory sex glands in heavy type stallions. In: *Proceedings of the 30th Conference on Physiology and Pathology of Reproduction*, Wien, 1997. *Reprod Dom Anim* 1997;32:45.

- [11] Malmgren L. Ultrasonography: a new diagnostic tool in stallions with genital tract infection? *Acta Vet Scand* 1992;88(Suppl):91–4.
- [12] McDonnell SM, Pozor MA. Accessory sex gland size and character differ between harem and bachelor stallions. Second International Workshop on Erection and Ejaculation in Horses and Men, Mount Joy, PA, 1995 [abstract].