

Use of imipramine hydrochloride for treatment of urospermia in a stallion with a dysfunctional bladder

R. M. Oristaglio Turner, VMD; C. C. Love, DVM; S. M. McDonnell, PhD; R. W. Sweeney, VMD;
E. D. Twitchell, VMD; P. L. Habecker, VMD; L. K. Reilly, VMD; M. A. Pozor, Med Vet;
R. M. Kenney, DVM, PhD

- Of the available treatments for urospermia in breeding stallions, none has been consistently satisfactory.
- Evacuation of the bladder prior to ejaculation, although often difficult to accomplish, is important in managing breeding stallions with urospermia.
- Orally administered imipramine hydrochloride reduced the frequency and degree of urospermia in a breeding stallion that was incapable of completely voiding its bladder.

An 8-year-old 600-kg Anglo-Norman stallion imported from Germany was referred for evaluation of recurrent urinary tract infections and unspecified genital tract infections. It was reported that the stallion dribbled urine, especially during exercise, and that urospermia had been detected when semen was collected in an artificial vagina. While in Germany, the stallion had been bred by natural cover to as many as 50 mares/y. Pregnancy data and detailed breeding records were not available. Findings on analysis of 1 ejaculate collected in Germany included 18.8×10^9 total sperm, pH 7.5, and total motility of 70%. There was a report of urospermia for 1 ejaculate prior to importation to the United States. During the stallion's first breeding season in the United States, 4 mares were bred, with 1 reported to be pregnant.

At the time of admission, a general physical examination revealed no abnormalities. Semen was collected into a Missouri artificial vagina, using an ovariectomized mare as a stimulus and mount mare. The stallion's libido was good. It readily developed and maintained a normal erection and mounted but failed to couple well during thrusting. During the first semen collection, the stallion ejaculated normally, but ejaculation was immediately followed by urination, which contaminated the ejaculate with approximately 20 ml of urine and 20 ml of sand-like urine sediment. This caused the ejaculate to appear opaque tan and to be malodorous. Initial sperm motility was 25% total and 15% progressive, and longevity of motility of extended sperm was poor, with less than 10% total motility 30 minutes after collection. One hour later, a second ejaculate was collected by use of an open-ended Missouri artificial vagina. This was done in an attempt

to obtain urine-free semen jets and determine at what point during ejaculation urine was emitted. All jets of this fractionated ejaculate were grossly normal, appearing translucent white with no obvious urine sediment. Initial motility was 40% total and 30% progressive. Bacteriologic culturing of a swab specimen of the second ejaculate yielded moderate growths of *Enterococcus* spp, an aerobic gram-positive rod, and a coagulase-negative *Staphylococcus* spp.

During semen collections into a standard Missouri artificial vagina over the next several days, it was observed that urine was not expressed in any predictable pattern and often was grossly evident in all jets of an ejaculate. Accordingly, fractionation was not attempted again.

As part of a complete behavioral evaluation, the horse was videotaped in his stall for a 24-hour period. The horse's posture during urination and the frequency and stream of urination were normal. Frequency and duration of masturbation, as well as penis control, were normal. Defecation frequency and posture also were normal. Once, the stallion leaned on the wall of the stall in an unusual posture, suggestive of a slight neurologic deficit. Urinary incontinence was not observed during the 24-hour period the stallion was videotaped or at any time during its stay.

The urinary bladder, accessory sex glands, caudal aorta, and iliac arteries were examined by palpation and ultrasonography per rectum. The bladder was full and contained urine and sediment. The sediment occupied approximately 50% of the total bladder volume. No other abnormalities were apparent. The bladder could not be expressed manually per rectum, which indicated the presence of some functional sphincter and bladder neck tone. The horse was then placed in a freshly bedded stall to encourage voluntary urination. The horse postured and urinated normally. Palpation and ultrasonography per rectum again were performed and, despite the apparently normal voluntary urination behavior, urine and sediment remained in the bladder. A detrusor sphincter muscle dyssynergia was suspected. A complete neurologic examination revealed no apparent deficits aside from the urinary tract. Specifically, cranial nerve function, hind limb function, anal tone, anal reflex, tail tone, and defecation were considered normal. There were no areas of cutaneous hypoalgesia.

Bacteriologic culturing of free-catch and catheterized urine samples yielded a heavy growth of nonpathogenic *Enterococcus* spp similar to that cultured from the semen. Grossly, the catheterized urine sample contained large amounts of urine sediment, similar to what appeared in

From the Department of Clinical Studies, New Bolton Center (Turner, Love, McDonnell, Pozor, Twitchell, Kenney, Sweeney) and the Department of Pathobiology (Habecker), School of Veterinary Medicine, University of Pennsylvania, 382 W Street Rd. Kennett Square, PA 19348-1692 Dr Twitchell's present address is 8784 Ennis Dr. Ene. PA 16509 Dr Reilly's present address is 2001 Sonora Ln, Manheim PA 17545

the ejaculate. Structural abnormalities were not detected via ultrasonography of the empty bladder after catheterization. Urinalysis results were normal, with the exception of an unusually large amount of amorphous phosphate crystals. Results of blood chemistry analyses were within normal limits.

To further evaluate the ability of the detrusor muscle to contract, bethanechol chloride[®] (0.07 mg/kg of body weight) was administered sc. Bethanechol is a cholinergic agent that normally causes evacuation of the bladder within 15 minutes of subcutaneous administration. The stallion urinated but did not completely evacuate the bladder, as determined by ultrasonography and palpation per rectum. At several times over the next 12 days, the bladder was palpated per rectum immediately after apparently normal voluntary urination. At no time was the bladder completely evacuated.

Over the next 7 days, semen was collected once or twice daily for a total of 8 samples. Urine was evident in 7 of the 8 ejaculates. The amount of urine contamination varied from minimal (pale yellow-tinged ejaculate; few urine crystals) to severe (ejaculate had the gross appearance of sediment-filled urine; large numbers of urine crystals). Spermatozoa morphologic characteristics were fair-to-good for all ejaculates (mean, 61% morphologically normal; range, 42 to 77% morphologically normal). Urine-contaminated samples had lower total and progressive motilities than did the urine-free sample. Less urine was in the second of 2 ejaculates collected in 1 day and in ejaculates collected immediately after the horse had voluntarily urinated. By placing the stallion in a freshly bedded stall and waiting for it to urinate prior to the second collection of the day, it was possible to collect ejaculates with reduced urine contamination. Longevity of motility of these ejaculates could be prolonged by use of a skim milk glucose extender. Despite these management efforts, we were unable to reliably collect an ejaculate that would be acceptable for breeding.

Because our methods for management of the urospermia proved unsatisfactory, the alpha-adrenergic agent imipramine hydrochloride (0.8 mg/kg) was administered orally in the feed 4 hours prior to semen collection to enhance bladder neck closure during ejaculation. Just prior to semen collection, the stallion was placed in a freshly bedded stall to stimulate voluntary urination. Immediately after the stallion had voided, semen was collected in a Missouri artificial vagina. The ejaculate was grossly free of urine contamination. Creatinine concentration in the ejaculate was within normal limits (0.5 mg/dl), confirming the absence of urine. A second ejaculate collected a half hour later contained only slight gross urine contamination (pale yellow, translucent ejaculate with minimal urinary sediment). This protocol was repeated the following day with similar results.

The horse was discharged with instructions to the owner to administer 500 mg of imipramine in the feed 2 to 3 hours prior to semen collection and to collect semen immediately after the stallion had voided. If the first ejaculate had gross urine contamination, a second ejaculate was to be collected 10 to 15 minutes later. Using this protocol, the stallion was used for breeding



Figure 1—Transrectal ultrasonogram of the bladder of a stallion with urospermia. The examination was performed immediately after the horse had voluntarily urinated. Residual hyperechoic urinary sediment is in the bladder lumen (large arrow) and the bladder wall (small arrows) appears moderately thickened. (5 MHz, linear)

for 2 breeding sessions. Of 20 mares bred, 19 became pregnant; information on cycles per pregnancy was not available. By the third year, the urospermia was no longer manageable, using the imipramine protocol. The stallion was admitted for reevaluation of refractory urospermia.

The urogenital tract was evaluated by palpation and ultrasonography per rectum. The bladder was greatly distended and approximately 80% of its total volume was comprised of urine sediment, a remarkable increase since the stallion's initial visit. When urinating voluntarily, the stallion would initially posture and urinate normally and then would walk around the stall while still voiding a small, steady stream of urine. This urination appeared to be passive, and the stallion appeared unaware that it was occurring. After the horse had urinated voluntarily, palpation and ultrasonography per rectum were repeated. Residual urine sediment was evident and the bladder wall appeared moderately thickened (Fig 1), suggesting chronic irritation. Urinary incontinence was not observed at any time between episodes of voluntary micturition.

A complete neurologic examination was performed; aside from the urinary tract, no abnormalities were found. Although no definitive diagnosis could be made, the progression of the urinary tract disorder with the development of passive urination while moving around the stall further supported the diagnosis of a reflex dysynergia of the bladder and urethral sphincter.

With the stallion sedated, a catheter was passed to obtain a urine sample for bacteriologic culture and susceptibility testing. Initially, relatively normal urine was obtained. As the more ventral area of the bladder was drained, the urine became extremely thick, sandy, and malodorous and appeared to consist primarily of sediment. The thin, urine-like portion of the sample and the malodorous, sandy portion of the sample were submitted for urinalysis and bacteriologic culturing and susceptibility testing. The urine-like portion yielded no growth on culture, and results of urinalysis were normal. Analysis of the urine sediment revealed high numbers of

WBC (6 to 10/high-power field) and large amounts of calcium carbonate crystals. A heavy, pure growth of *Staphylococcus* spp was isolated. Treatment with sulfamethoxazole trimethoprim was initiated (30 mg/kg, po, q 12 h).

Numerous ejaculates were collected over the next week, using the techniques previously discussed (fractionation, voluntary urination prior to ejaculation, oral administration of imipramine), with inconsistent results regarding degree of urine contamination. In a further attempt to control the urospermia, phenylpropanolamine, another alpha-adrenergic agent, was administered (0.35 mg/kg) in the feed 2 times daily for 14 days. There was no apparent improvement.

Two attempts were made to induce standing ex copula ejaculation using xylazine and clomipramine hydrochloride.¹ It was thought that ejaculation induced with the stallion standing would not involve an increase in abdominal or intravesicular pressure, and thus, urethral sphincter competence might remain sufficient to prevent urine contamination. For both trials, prespermatozoa droppings containing urinary sediment were collected, and ejaculation did not occur. Attempts to pharmacologically induce ejaculation were discontinued.

In a further attempt to obtain a urine-free ejaculate and as treatment for the bacterial cystitis, a urinary catheter was passed, and the bladder was lavaged with sterile 0.9% NaCl solution.^d At the conclusion of the lavage and before the catheter was withdrawn, the bladder was fully evacuated of any residual sediment by manual expression per rectum. Immediately afterward, the catheter was removed, and semen was collected by use of a Missouri artificial vagina. A urine-free ejaculate was obtained. This protocol was used 7 times to obtain urine-free ejaculates. Four of these ejaculates were extended and transported at 4 C for artificial insemination; 3 ejaculates were frozen, using techniques described by Love et al.² Variations from this protocol (collection without prior catheterization, catheterization and lavage without manual evacuation of the bladder) resulted in gross urine contamination of the ejaculate. The stallion was given sulfamethoxazole trimethoprim throughout its stay (20 days) to reduce the risk of further bacterial cystitis. Because of the expense and complicated protocol necessary to obtain satisfactory ejaculates from this stallion for breeding, the owners elected to stockpile frozen semen for future breedings and discontinue use of fresh or fresh-transported semen. To our knowledge, the stallion was not used again for breeding by natural cover or by artificial insemination with fresh semen. One mare bred over 1 cycle with urine-free semen collected and frozen following the catheterization protocol became pregnant.

Three-and-a-half years after initial admission, the stallion was again admitted, this time for evaluation of acute neurologic disease. During the 72 hours prior to admission, the stallion had become severely atactic and had experienced urinary incontinence, hematuria, and cystitis. The stallion was treated at the farm with procaine penicillin G, a potentiated sulfonamide, and ammonium chloride, with no apparent improvement. Results of a blood titer for antibodies against *Sarcocystis neurona*, the causative organism of equine protozoal myelitis, were inconclusive.

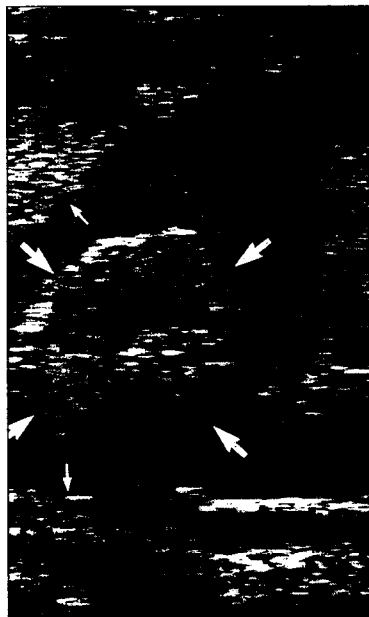


Figure 2—Transrectal ultrasonogram of the bladder of the same stallion 3.5 years after initial admission. Soft-tissue masses (large arrows) surrounded by urine and sediment can be seen protruding from the bladder wall (small arrows) into the bladder lumen. (5 MHz, linear)

On admission, the stallion had marked hind limb ataxia. The right hind limb was more severely affected. Proprioceptive deficits were apparent, and the horse nearly fell several times. The forelimbs appeared normal. Cranial nerve responses were within normal limits. A general physical examination revealed bilaterally harsh lung sounds and atrophy of the long muscles of the back and gluteal muscles. The stallion was alert and had a good appetite. The stallion frequently dribbled small amounts of bloody urine. Serum biochemical analysis revealed mild hypokalemia (2.0 mEq/L) and mildly high activities of -glutamyltransferase (34 IU/L) and creatinine phosphokinase (181 IU/L). Complete blood count revealed leukocytosis (13,700 WBC/ μ l) and neutrophilia (12,741 WBC/ μ l). The bladder was catheterized, and a urine sample was obtained for bacteriologic culture. Urine was grossly blood-tinged and contained a large amount of malodorous sediment. Urinalysis revealed blood (+4/4) and protein (+3/4) in addition to 2 to 4 w&high-power field. Many cells were too degenerated to identify. Numerous gram-positive and gram-negative bacteria also were seen, and *Proteus mirabilis* was isolated. Abdominocentesis was unsuccessful.

Abdominal palpation revealed numerous 3- to 7-cm firm masses around the bladder neck, the caudal aorta and iliac vessels, caudal spinal column, and pelvis. Ultrasonography of the masses revealed a homogeneous mottled gray appearance. The masses associated with the bladder protruded into the bladder lumen (Fig 2), and masses associated with the iliac vessels partially occluded the lumen. A fiberoptic endoscope was passed through the urethra into the bladder to inspect and possibly biopsy the masses; however, foamy urine and residual sediment made adequate inspection impossible.

On the basis of the stallion's history and clinical signs, malignant neoplasia was suspected. Because of the prognosis, the owner elected euthanasia. Prior to euthanating the animal, an attempt was made to induce ex copula ejaculation using clomipramine (2.2 mg/kg, IV) to collect semen for freezing. An ejaculate was not

obtained. Use of xylazine to induce ejaculation was considered inappropriate for the horse because of severe ataxia.

Following euthanasia, the testicles were removed, and sperm was aspirated from the epididymal tails and frozen by standard means. Postthaw motility was poor (20% total and 10% progressive) and deemed unacceptable for breeding. Cerebrospinal fluid obtained post-mortem by atlanto-occipital puncture was within normal limits.

Necropsy examination revealed transitional cell carcinoma of the bladder with extension to the retroperitoneum and spinal canal, carcinomatosis of the peritoneal cavity, and metastasis to the lung. Severe, multifocal, chronic-active thrombosis of the pulmonary arteries also was evident, as was severe, subacute, focal thrombosis of the common iliac vein. The lack of microscopic damage to the lumbar and sacral segments of the spinal cord suggested that the hind limb ataxia was most likely caused by peripheral nerve compression, the iliac vein thrombus, or a combination of both.

Urospermia is an uncommon problem in stallions,³ and little information is available on its pathogenesis and treatment. Urospermia can develop as an isolated disorder or can be associated with other primary neurologic abnormalities, such as neuritis of the cauda equina, equine herpesvirus I, and sorghum toxicosis. Urospermia also can develop secondary to fractures, osteomyelitis, and neoplasia.³⁻⁵ In the stallion reported here, the neurologic lesions initially appeared to be isolated to the bladder, unlike the earlier-described problems, which all typically result in multiple deficits. Nonetheless, these problems were not completely ruled out. The unusual leaning posture of the stallion noticed during the first visit could have been a subtle sign of other underlying neurologic deficits. The most probable cause of the inappropriate urination was initially believed to be a reflex dyssynergia between the bladder afferents and the urethral sphincter efferents. In animals with bladder dyssynergia, urination occurs only when intravesicular pressure exceeds urethral sphincter pressure, which results in a large postvoiding residual urine volume.

At the time of the third examination, neurologic deficits were apparent, and there were palpable masses in the abdomen. Transitional cell carcinoma of the urinary bladder with abdominal and thoracic metastasis was diagnosed. Tumors of the urinary tract of the horse are uncommon.^{6,7} Squamous cell carcinoma is the most frequently reported tumor of the equine urinary bladder.⁸ Two cases of transitional cell carcinoma of the urinary bladder, 1 case of transitional cell carcinoma of the urethra, and 1 case of transitional cell carcinoma of the renal pelvis have been reported in horses.⁸⁻¹¹ Weight loss and hematuria are the most common clinical signs, and typically, the clinical history is short (< 3 months).^{8,9} It is, nonetheless, possible that the neoplasia in this stallion had been evident since the initial visit, remaining clinically undetectable for a 3.5-year period despite numerous examinations. Once the tumor progressed, more overt clinical signs developed, seemingly acutely. Alternatively, it is possible that the chronic irritation and infection of the bladder predisposed the stallion to bladder neoplasia. In human beings, chronic irritation of the

bladder can lead to squamous metaplasia, which in turn may lead to carcinomas.¹² Thus, the transitional cell carcinoma in this report may have developed secondarily to an underlying, chronic primary bladder dysfunction such as a reflex dyssynergia. A final possibility is that the bladder dysfunction and neoplasia were completely unrelated.

Of the limited therapeutic options available for the treatment of urospermia in stallions, none has been consistently satisfactory. Encouraging the horse to urinate immediately prior to ejaculation has been suggested.¹³ Techniques for inducing urination in stallions include movement to a freshly bedded stall, placement of feces from another stallion in the subject stallion's stall, and the use of diuretics.¹³⁻¹⁵ The stallion of this report was unable to completely evacuate his bladder, so these techniques were inadequate. Fractionation of the ejaculate also has been suggested as a means to manage urospermia. Theoretically, a urine-free ejaculate could be obtained by collecting only the urine-free jets.^{14,16,17} This technique can be satisfactory if urine contamination occurs only in the final jets of the ejaculate. Unfortunately, the pattern of urine contamination during ejaculation is not always repeated in an affected individual, as was the case in the stallion of this report. In addition, urine may be in all fractions of the ejaculate. In the stallion of this report, fractionation proved inadequate as a reliable means of obtaining a urine-free sample.

Pharmacologic methods have been used in an attempt to control urospermia. Bethanechol chloride and flavoxate hydrochloride have been used with mixed results.¹⁶ Oxytocin also has been suggested as a means of constricting the bladder neck¹⁸; however, results are reportedly poor. Beta-blocking agents also have been tried with no effect.¹³

Bladder neck closure during ejaculation is believed to be primarily an alpha-adrenergic event.¹⁹ Thus, the use of alpha-adrenergic drugs to support bladder neck closure is a logical therapeutic option. Imipramine, a tricyclic antidepressant, is a derivative of dibenzazepine and related to the phenothiazines.²⁰ In human beings, its principle use is in the treatment of major depression; however, it has been successfully used to treat retrograde ejaculation.^{21,22} Its alpha-adrenergic effects are believed to increase bladder neck sphincter and urethral pressure in dogs.²³ Although the syndrome of urospermia in stallions and of retrograde ejaculation in human beings have different clinical signs, the underlying problem is probably similar (ie, incomplete closure of the bladder neck during ejaculation). Thus, it is not unexpected that drugs used successfully to treat retrograde ejaculation in men may also be beneficial to stallions with urospermia. Other alpha-adrenergic agents that have been used in men for treatment of retrograde ejaculation include clomipramine,²⁴ ephedrine,²⁵ and synephrine.²⁶ The alpha-adrenergic agent noradrenaline has been used to treat urospermia in a stallion but resulted in *no* improvement.¹³ For the stallion reported here, imipramine was selected after consultation with an andrologist, because its safety for use in horses was documented, and because a safe starting dose range for horses had been established.¹⁹

Placement of a urinary catheter to facilitate complete

evacuation of urine and all sediment in the bladder also has been suggested; however, routine use of this method predisposes the horse to bacterial cystitis.¹⁶ In the stallion of this report, even after the urospermia had become severe, urinary catheterization, combined with manual evacuation of the bladder per rectum, proved to be a reliable method of collecting a urine-free ejaculate. The owner was informed of the risks of repeated bladder catheterization, but elected to continue with the procedure to honor contracts with mare owners.

We were able to closely follow the progression of a case of chronic urospermia in a stallion over a 3.5-year period and, thus, had the opportunity to apply several previously reported treatments and 1 novel treatment for urospermia in the stallion. Imipramine, combined with other management changes, reduced the frequency and degree of urospermia in an affected stallion for approximately 2 years. The increased bladder neck sphincter pressure caused by the alpha-adrenergic effects of imipramine may, at least initially, have provided sufficient resistance to contain urine and urine sediment within the dysfunctional bladder. When used in men at higher dosages, imipramine has been implicated as a cause of ejaculatory failure, erectile dysfunction, and impotence,^{27,28} so dosage and administration in horses should be carefully monitored.

^aUrecholine, Merck, Sharp & Dohme, West Point, Pa.

^bUnited Research Laboratories Inc, Bensalem, Pa.

^cUnited Research Laboratories Inc, Bensalem, Pa.

^dAbbott Laboratories, North Chicago, Ill.

References

1. McDonnell SM, Love CC. Xylazine-induced ex copula ejaculation in stallions. *Theriogenology* 1991;36:73-76.
2. Love CC, Loch WL, Bristol F, et al. Comparison of pregnancy rates achieved with frozen semen using two packaging methods. *Theriogenology* 1989;31:613-622.
3. Blanchard TL, Vamer DD, Bretzlaff KN, et al. Diseases of the reproductive system: male reproductive disorders. In: Smith B, ed. *Large animal internal medicine*. St Louis: The CV Mosby Co, 1990;1424.
4. McClure JJ. Paralytic bladder. In: Robinson EN, ed. *Current therapy in equine medicine 2*. Philadelphia: WB Saunders Co, 1987;712.
5. Mayhew IG. Neurologic aspects of urospermia in the horse. *Equine Vet Educ* 1990;2:68-69.
6. Cotchin E. A general survey of tumors in the horse. *Equine Vet J* 1977;9:16-21.
7. Misdorp W. Tumors in large domestic animals in the Netherlands. *J Comp Pathol* 1967;77:211-217.
8. Fischer AT, Spier S, Carlson GP, et al. Neoplasia of the equine

urinary bladder as a cause of hematuria. *J Am Vet Med Assoc* 1985;186:1294-1296.

9. Traub JL, Bayly WM, Reed SM, et al. Intraabdominal neoplasia as a cause of chronic weight loss in the horse. *Compend Contin Educ Pract Vet* 1983;5:S526-S536.

10. Lloyd KCK, Wheat JD, Ryan AM, et al. Ulceration in the proximal portion of the urethra as a cause of hematuria in horses: four cases (1978-1985). *J Am Vet Med Assoc* 1989;194:1324-1326.

11. Servantie J, Magnol JP, Regnier A, et al. Carcinoma of the renal pelvis with bony metaplasia in a horse. *Equine Vet J* 1986;18:236-238.

12. Koss LG. Tumors of the urinary bladder. In: Koss LG, Firinginger HI, eds. *Atlas of tumor pathology*. Washington, DC: Armed Forces Institute of Pathology, 1975;103.

13. Leendertse IP, Asbury AC, Boening KJ, et al. Successful management of persistent urination during ejaculation in a Thoroughbred stallion. *Equine Vet Educ* 1990;2:62-64.

14. Hurtgen J. Stallion genital abnormalities. In: Robinson NE, ed. *Current therapy in equine medicine 2*. Philadelphia: WB Saunders Co, 1987;561.

15. Held JP, McCracken MD, Toal R, et al. Epididymal swelling attributable to generalized lymphosarcoma in a stallion. *J Am Vet Med Assoc* 1992;201:1913-1915.

16. Vamer DD, Schumacher J, Blanchard TL, et al. Diseases and management of breeding stallions. Goleta, Calif: American Veterinary Publications, 1991;337-340.

17. Nash JG, Voss JL, Squires EL. Urination during ejaculation in a stallion. *J Am Vet Med Assoc* 1980;176:224-227.

18. Voss JL, McKinnon AO. Hemospermia and urospermia. In: *Equine reproduction*. Philadelphia: Lea & Febiger, 1993.

19. McDonnell SM. Pharmacologically-induced ex copula ejaculation in stallions, in *Proceedings. 12th Int Cong Anim Reprod* 1992;4:1894-1896.

20. Baldessarini RJ. Drugs and the treatment of psychiatric disorders. In: Gilman AG, Goodman LS, Rall TW, et al, eds. *The pharmacological basis of therapeutics*. 7th ed. New York: MacMillan Publishing Co, 1985;413-415.

21. Brooks ME, Berezin M, Braff Z. Treatment of retrograde ejaculation with imipramine. *Urology* 1980;15:353-355.

22. Brooks ME, Sidi A. Treatment of retrograde ejaculation using imipramine (lett). *Urology* 1981;18:633.

23. Khanna OP, Elkouss GC, Heber DL, et al. Imipramine HCl: pharmacodynamic effect on the lower urinary tract of female dogs. *Urology* 1975;6:49-51.

24. Eppel SM, Berzm M. Pregnancy following treatment of retrograde ejaculation with clomipramine hydrochloride. A report of 3 cases. *S Afr Med J* 1984;66:889-891.

25. Stewart BH, Bergant JA. Correction of retrograde ejaculation by sympathomimetic medication. Preliminary report. *Fertil Steril* 1974;25:1073-1074.

26. Stockamp K, Schreiter F, Altwein JE. Alpha adrenergic drugs in retrograde ejaculation. *Fertil Steril* 1974;25:817-820.

27. Segraves RT. Sexual side-effects of psychiatric drugs. *Int J Psychiatry Med* 1988;18:243-252.

28. Segraves RT. Effects of psychiatric drugs on human erection and ejaculation. *Arch Gen Psychiatry* 1989;46:275-284.